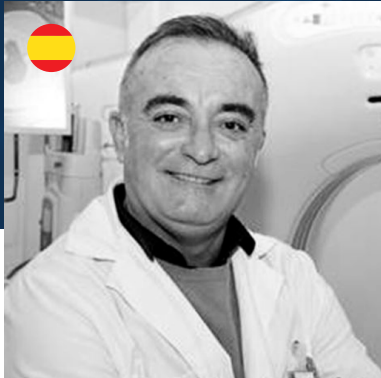

INTERVIEW

Current and future place of Radiology in the COVID-19 management: **impacts and adjustments.**

The view of European Radiologists.



Fernando Alarza

Director of the Central Radiodiagnosis Unit in the Community of Madrid – Spain



Davide Ippolito


Director Emergency Radiology Unit Azienda Ospedaliera San Gerardo, Monza – Italy




Antoine Khalil

Director of Radiology and Medical Imaging, Bichat Hospital, Paris – France

1 Can you explain the place of radiology in your national guidelines and policies for the surveillance, diagnosis and follow-up of suspected and diagnosed COVID-19 patients?

 **F. Alarza:** Radiology has been one of the most important diagnostic tools during the COVID-19 crisis. Chest X-rays were used initially as a first screening test to rule out pulmonary infection when a symptomatic patient arrived at the hospital. Chest CT was also used in several hospitals when available because it is more sensitive. Chest X-rays are currently used as a follow-up tool.

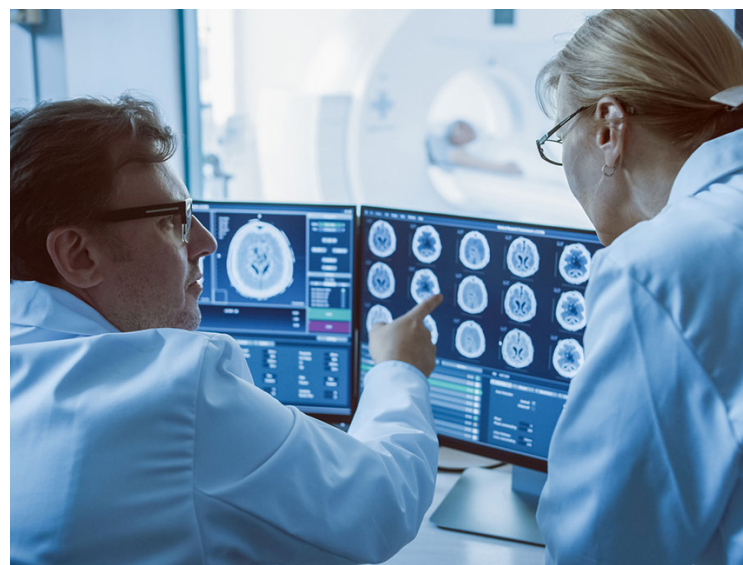Guidelines suggest a control after 8 weeks, especially in symptomatic patients (cough, shortness of breath, etc.) and for those who required intensive care unit management. CT can also be used in the acute phase and during follow-up.

 **D. Ippolito:** Based on current clinical experience, lung imaging alterations occur earlier than clinical symptoms, so radiological imaging plays an important role in screening, diagnosis and management of SARS-CoV-2 pneumonia.

The guidelines from the Italian Society of Medical Radiology (SIRM) for COVID-19 patients recommend X-ray, computed tomography and ultrasound examinations.

Chest radiography is a relatively cheap method that can quickly establish the presence or absence of pneumonia in addition to its extent and location, and also detect some possible complications such as pleural effusion. Moreover, based on our experience, chest X-rays can potentially serve as a screening test if combined with a RT-PCR test in emergency settings, especially in areas with high disease prevalence, in order to choose the appropriate treatment regimen for patients. In an emergency setting, chest X-rays are in fact a key tool in diagnostic work-up for patients with suspected infection.


As for CT, this can detect abnormalities not easily recognized in a chest radiograph, especially if less extensive, because it is more sensitive. It is also a quick tool for determining whether a patient is infected with COVID-19 or not, especially when the RT-PCR test is potentially false negative. According to the American College of Radiology, this technique should not be considered as a screening method, not only to reduce radiation dose exposure, but also because use of CT in this pandemic setting is quite complex, especially in emergency departments, due to time-consuming decontamination procedures that must



be respected in the CT room after each patient to avoid any cross infection.

Therefore, we use this technique only when necessary in order to determine the severity of lung involvement, to rapidly diagnose patients affected by severe symptoms to place them in a specific coronavirus intensive surveillance unit or, finally, to exclude additional complications such as barotrauma and pulmonary embolism.

Lastly, we use ultrasound as a complementary imaging tool to assess the effectiveness of pronosupination movements.

 **A. Khalil:** The French policy placed radiology at the center of COVID-19 patient management in response to the pandemic. From the beginning of the outbreak, our French Society of Thoracic Imaging proposed guidelines explaining how to manage and use chest CT scans while protecting physicians and technicians.

Chest CT scanners became the main tool for diagnosing and establishing the severity of COVID-19 pneumonia, depending on CT scan availability and possibilities for development. In some situations, in particular if there was a high influx of patients, chest CT scans were used as a triage tool, to orient patients towards COVID-19 positive and COVID-19 negative areas prior to hospitalization. Imaging is not recommended for patients suspected to be infected with COVID-19 but who do not require hospitalization.

Radiology was an important tool in COVID-19 patient follow-up to diagnose thromboembolism disease (venous thrombosis or pulmonary emboli), as an explanation why pneumonia might be worsening. Other organs are also involved in COVID-19, including the heart (myocarditis), brain (infarction and encephalopathy) and veins (vascular thrombosis).

The role of radiology in long-term follow-up has still to be determined, especially for patients in whom organs like the lungs, heart and brain have suffered severe damage.

2 Can you explain the place of contrast-enhanced chest CT and its benefits for suspected and diagnosed COVID-19 patients?

FA: At the beginning of the pandemic phase, I received information about local thrombotic event caused by COVID infection, so I thought it might be a good idea to use contrast-enhanced chest CT for diagnosed patients with bad clinical progression (as opposed to the initial diagnostic CT). There was no evidence available and not enough scientific proof, so we decided not to use it. Later, all the studies basically demonstrated a high prevalence of pulmonary thromboembolism or focal lung thrombus, so we performed contrast-enhanced CT in all our patients.

DI: Based on recent clinical experience, patients infected with SARS-CoV-2 are at high-risk in developing pulmonary embolism, caused mainly by direct endothelial cell injury in microvessels with subsequent release of the damaged endothelial cells into the bloodstream. The acute inflammatory state leading to hypercoagulability combined with immobilization, respiratory failure, mechanical ventilation and use of a central venous catheter are also considered potential additional thromboembolism-inducing factors in SARS-CoV-2 patients.

Therefore, a correct understanding of this risk allows early diagnosis and treatment the SARS-CoV-2 complications. In our hospitals, about 45% of the total number of patients with suspected pulmonary embolism that underwent CT pulmonary angiography (CTPA) showed a massive or sub-massive pulmonary embolism, despite no major risk factors for VTE and having received, according to their

D-dimer score, either prophylactic or full anticoagulation therapy before the CTPA examination.

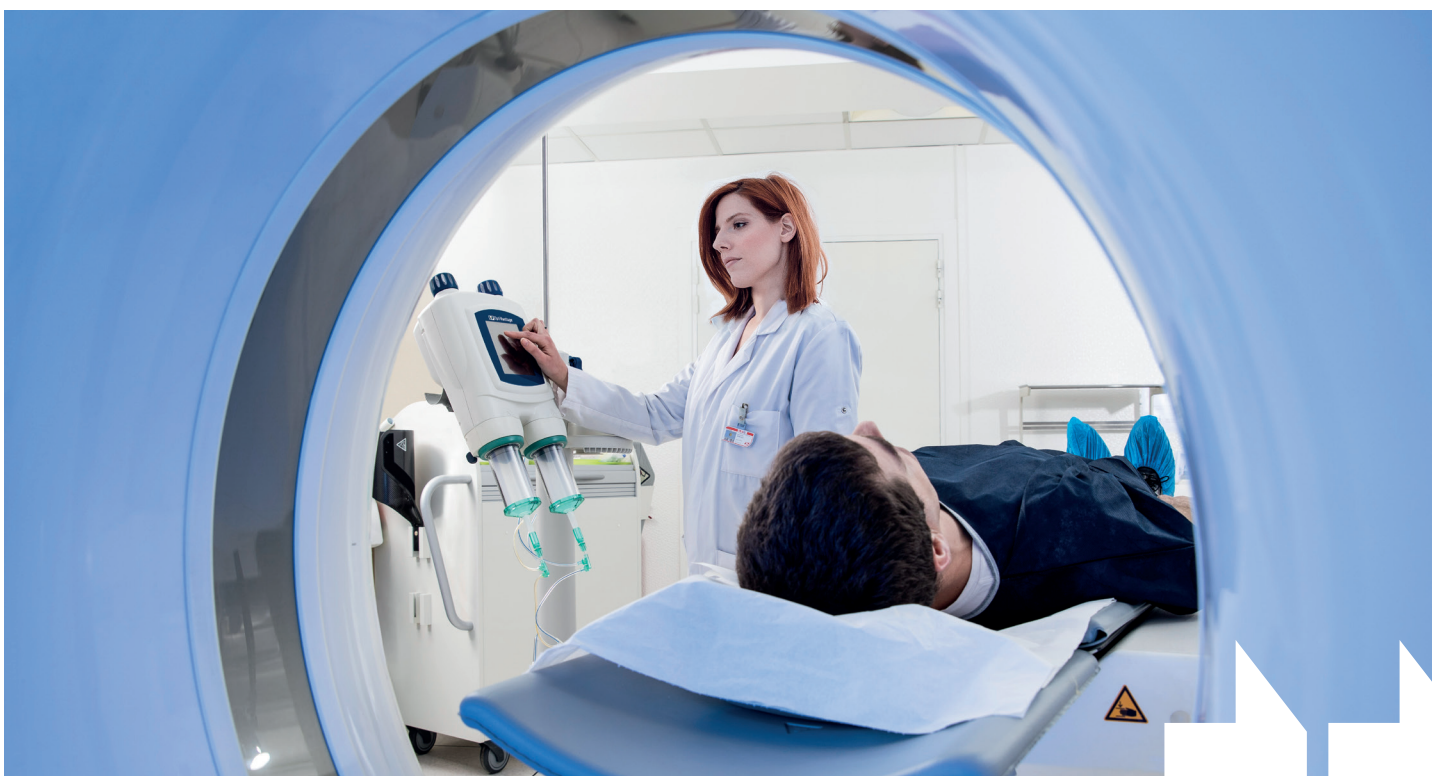These results have shown and confirmed the higher risk of developing thromboembolism, underlining the need for D-Dimer evaluation and other coagulation tests when managing these patients in order to regularly assess the risks.

Moreover, it should be pointed out that development of microthrombi may be encountered also in brain circulation, causing an "ischemic stroke" event, which should be carefully evaluated first with an unenhanced brain CT scan and later with an angiographic CT study of brain artery vessels (Willis circle). In this scenario, a CT scan with a contrast agent, including also CTPA, is one of the best diagnostic tools for evaluating both parenchymal and possible vessel involvement, making it a useful technique for effective clinical patient management.


Additional possible uses of contrast-enhanced CT include assessment of abdominal organ involvement in COVID-19 infections, in which case both bowel and several solid organs can show signs of architectural and vascular damage.

AK: The main symptom of patients with COVID-19 or suspected to have COVID-19 is dyspnea with a high suspicion of pulmonary embolism. The D-dimer levels are also very high in patients with severe COVID-19, and not discriminative.


If a patient has mild pneumonia and a disproportionate O₂ saturation, CT angiography is required to rule out diagnosis of pulmonary embolism.



3 Are you expecting new complications due to COVID-19 pneumonia in the coming weeks? If so, what would be the place of radiological techniques?

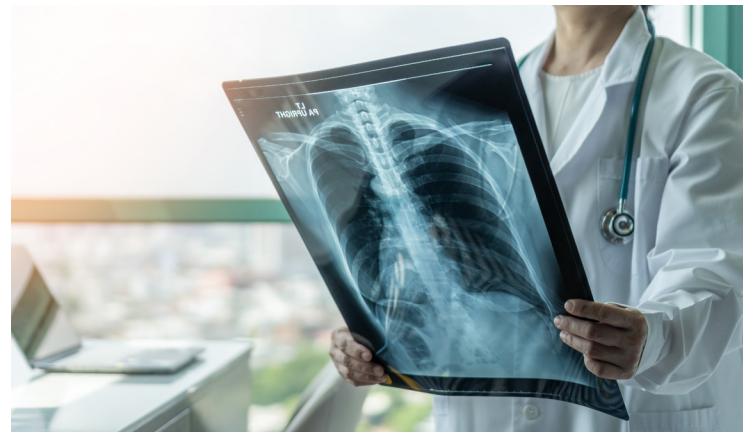 **FA:** In my opinion chest CT will have an important role to play in various scenarios:

- Patients with shortness of breath following the infection, with no other complications, and not having previously had a CT scan will probably need a contrast-enhanced CT to rule out previous non-detected embolic lung disease. However in my opinion the results will probably be negative in most of the cases because it is difficult to be sufficiently accurate when studying very distal small vessels. In some centers, where dual-energy CT is available, iodine maps could be used, but we do not yet have enough data ;
- In cases of previous thromboembolic disease, CT will be useful for ruling out secondary pulmonary hypertension;
- CT will also be used to demonstrate mid/long-term lung complications, such as organizing pneumonia, lung fibrosis, etc. In my opinion, this will likely concern patients who were treated in intensive care units. Many probably suffered diffuse alveolar damage or respiratory distress and should develop some type of residual image.

 **DI:** There is a growing amount of published data showing that COVID-19 complications are not limited to the pulmonary system, and even if SARS-CoV-2 is considered a lung infection, it has been ascertained that it causes blood clots that can lead to severe complications, like brain stroke, gastrointestinal inflammations and myocarditis, which suggests that the virus affects different structures on the lining of blood vessels throughout the body.

This coronavirus has been declared to cause the development of microthrombi, which could be carried to the lungs and obstruct blood flow, a condition called "pulmonary embolism". If the microthrombi reach brain circulation, they will cause an ischemic stroke, and our recent clinical experience shows that the number of ischemic events during the COVID-19 outbreak has increased.

In the cardiac domain, the inflammation of the vascular system can result in diffuse microangiopathy with thrombosis; the inflammation of the myocardium can also result in myocarditis, heart failure, arrhythmias and acute coronary syndrome with rapid deterioration. More precisely, acute myocardial injury has been reported




in 7% to 20% of patients, and at hospital admission this event has been associated with a higher risk of all-cause mortality in patients with COVID-19.

In the pediatric domain, it has been shown that a small number of children and adolescents who develop a significant systemic inflammatory response, a cytokine release syndrome, had prolonged fever (5 days or more) with gastrointestinal symptoms, with or without rash.

Moreover, in the Italian region of Lombardy, a rare syndrome has been found that shares feature common in Kawasaki disease, such as toxic shock syndrome, bacterial meningitis and macrophage activation syndromes. Common signs include abdominal pain, other gastrointestinal symptoms and cardiac inflammation. However, only a few patients have developed this syndrome and insufficient information has been gathered about it, so further investigations are needed to clarify the origin of the symptoms and any possible treatment.

Therefore, the wide range of possible manifestations of SARS-CoV-2 infection (ranging from brain to lung to abdominal disease) have strengthened the role of radiology during this outbreak, both for diagnosing the disease and for long-term management during follow-up to monitor all possible overall body complications.

The number of lung CT scan examinations will probably increase in the next few months, and their main role may be to quantify the volume of pulmonary fibrotic bands as a residual sign of previous lung involvement. Usually, according to the COVID CT scoring system, stage 4 (final stage) of this disease is characterized by the development of fibrotic bands associated with architectural lung distortion, which can appear from 14 days after symptoms begin until several months later.

 **AK:** We suspect lung fibrosis to develop in line with what has already been published for patients with SARS-CoV-1. CT scans play a role in the early diagnosis of this disease alongside other functional lung tests. Use of contrast media could also be helpful for ruling out pulmonary embolism in these cases.

4 How might current and potential new complications influence clinical management?

DI: In the next few months, hospitals will need to recover the huge number of patients who had missed their follow-ups in the past couple of months due to this pandemic event.

In these last weeks, we have resumed our routine radiological workflow, which has drastically increased, firstly because we have to catch up on the high volume of exams that had been suspended and had been accumulating during the outbreak of the disease and following lockdown, and secondly because we also need to perform standard daily examinations. In addition, we now have to deal with a new kind of long-term COVID-related complication, because the impaired lung function caused by SARS-CoV-2 infection can negatively affect other organs like the heart, kidneys and brain, having significant health impacts that appear to also last after getting over the infection. A new dedicated area and radiology time slots are needed to manage possible new COVID-19 complications, in order to offer the best healthcare support to this group of patients while avoiding any risk of re-infection or cross-infection of non-COVID-19 patients. This will probably mean rethinking the organization of wards, in particular in radiology. It will then become necessary to create a reference COVID-19 center.

AK: We are progressively learning how to manage these patients and adapting to the situation from week to week, as new publications are published. But we must remain sufficiently critical of the published data to adapt our management of these patients.

5 How do patients (COVID-19 and non-COVID-19) react when they are referred for radiology tests?

DI: In the early stage of the pandemic, when people had not yet realized the high risk of contagion and potential severity of the COVID infection, patients would still go to hospitals for their routine diagnostic examinations, such as US, CT and X-Ray examinations, even without the appropriate protective equipment such as a mask.

After a few days, the SARS-CoV-2 infection spread rapidly, especially in the northern part of Italy, with a huge number of hospitalized patients and a high increase in deaths; for this reason, some hospitals in Lombardy, including ours, became a reference site for COVID-19 patients with five dedicated COVID intensive care units.

In this context, there was a considerable decrease in outpatient services, in particular in first aid access for trauma, as well as for abdominal, thoracic and musculoskeletal pain and common diagnostic tests, because most patients were very afraid of being infected. For the same reason, we tried to limit the number of requests for diagnostic examinations such as abdomen CT scans, US and X-rays, unless strictly necessary.

All citizens were in lockdown, and those with a fever, dyspnea or in any respiratory distress were asked to call a local emergency number that would instruct them on what to do based on the severity of their illness. Therefore, patients who showed up at the emergency department were almost exclusively those in respiratory distress or with other respiratory symptoms typical of COVID infection. They would undergo different types of imaging, for example chest X-rays, as a first-line treatment, or chest CTs if a deeper investigation was necessary.

AK: Patients are curious and frightened by the pandemic. Many patients have deserted the radiology departments, particularly in centers managing COVID-19 patients. Patients have generally chosen private centers for their radiology tests, to distance themselves from these COVID-19 patient centers.

6 How has COVID-19 impacted your local organization in the radiology department?

FA: I could write a book on this... there were two main scenarios:

I am the clinical manager of six hospitals in the Community of Madrid, each with a Head of Radiology.

Basically, these centers were organized as follows:

- Different circuits to differentiate between patients already diagnosed with COVID-19, those who were probably COVID-19 patients (not sure), and those in whom COVID-19 infection was not suspected, in order to avoid any contact amongst them;
- Radiology technicians reassigned to each circuit ensure appropriate prophylactic measures were taken for workers.

I was one of the radiology managers at the hospital created for COVID-19 patients.

- All our patients were COVID-19 patients, and the main problems for us involved creating a radiological unit from nothing in just five days, with all the IT issues that raises, to be able to issue a radiological report in a timely manner for all the radiology examinations performed. This included emergency radiology.

DI: The radiology staff are among the frontline teams when dealing with the management of COVID-19 patients, so we have had to organize the actual department differently in the past three months and establish clear infection control guidelines and working protocols for infection containment.

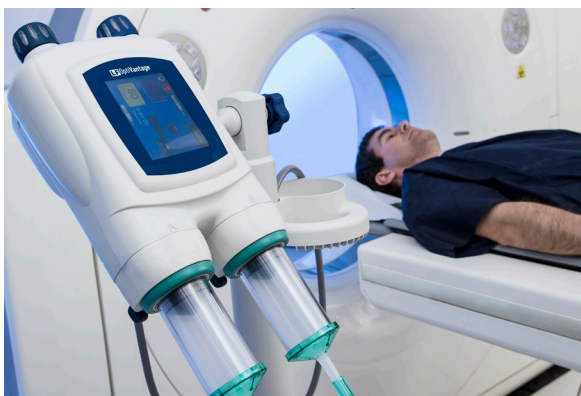The first step we took in our radiology department was to mark out specific radiology areas, creating a clear distinction between a “clean pathway” and “dirty pathway”. This allowed us to avoid any possible cross-infection between patients tested positive for COVID-19 infections and those tested negative. More specifically, we dedicated a CT scanner room and an MRI room to positive patients, with dedicated supplies of protective equipment for the staff and an external non-medical support team in charge of sanitizing the rooms many times a day.

In the emergency department, we made extensive use of portable X-ray machines, at patients’ bedsides. We used them for patients suspected to have or who had tested positive for SARS-CoV-2 infection in need of general radiography examinations. This prevented them from mixing with non-COVID-19 patients and limited the number of people moving around wards. For this, we used a dedicated auxiliary room in a newly-dedicated pre-triage area located at the entrance of the hospital.

Thanks to this approach, we were able to reduce to a minimum the disruption and discontinuity of radiology services and save a lot of time on cleaning and sanitizing radiology equipment. We also reduced the theoretical risk of cross-infection, because the surfaces of portable units can be easily cleaned. If patients had to be moved around wards, they had to wear a mask.

For all these reasons, we agree with the American College of Radiology when it says that use of CT implies a huge burden for radiology departments and is a big challenge for infection containment. In addition, we recommend that imaging examinations be performed by two radiographers, in pairs, so that if one gets contaminated during the procedure, the “clean” one can take over, avoiding contamination of other people/equipment.

AK: The COVID-19 pandemic has affected in real-time how we organized our radiology department locally. To ensure patient and staff safety, we adapted our organization every 24-48 hours according to the flow of patients. We began by booking a scanner for 3 hours a day with a special patient circuit. At the peak of the COVID-19 pandemic, we reserved 2 scanners 24 hours a day. We resumed our pre-COVID-19 organizational practices at the beginning of June.



7 Do you think these impacts could bring about long-term changes in your daily practice? Are you expecting the number of radiology tests to slow down or increase in the coming months?

FA: Of course, there will be long-term changes. I think radiology tests will probably be increased in the immediate future, and after that it will depend on how the virus evolves.

DI: Given the new social distancing rules for patients, the waiting room and time slots for each examination must be organized according to the different phases of disease infection, and rearranged weekly. From a clinical point of view, it has meant that we had to significantly reduce the number of examinations each day in the early phases of the disease.

In these last weeks, we have resumed our routine radiological workflow, which has drastically increased, firstly because we have to catch up on the high volume of exams that had been suspended and had been accumulating during the outbreak of the disease and following lockdown, and secondly because we also need to perform standard daily examinations. In addition, we now have to deal with a new kind of long-term COVID-19-related complications, because the impaired lung function caused by SARS-CoV-2 infection can negatively affect other organs like heart, kidneys and brain.

This new approach merits further resources and working time, as well as a reorganization of work shifts and of the number of people working each shift, to manage the entire workload efficiently in terms of staff and radiological equipment.

AK: The COVID-19 pandemic has had a major impact on our daily practice. All the radiology staff wear a mask and disinfect their hands regularly with a hydro-alcoholic hand solution during the day, especially when caring for patients. This is not something we did before the COVID-19 pandemic. Furthermore, social distancing, which requires that we maintain a distance of at least one meter between each person (radiology staff and patients), has reduced patient flows and affected our management of outpatients and inpatients.

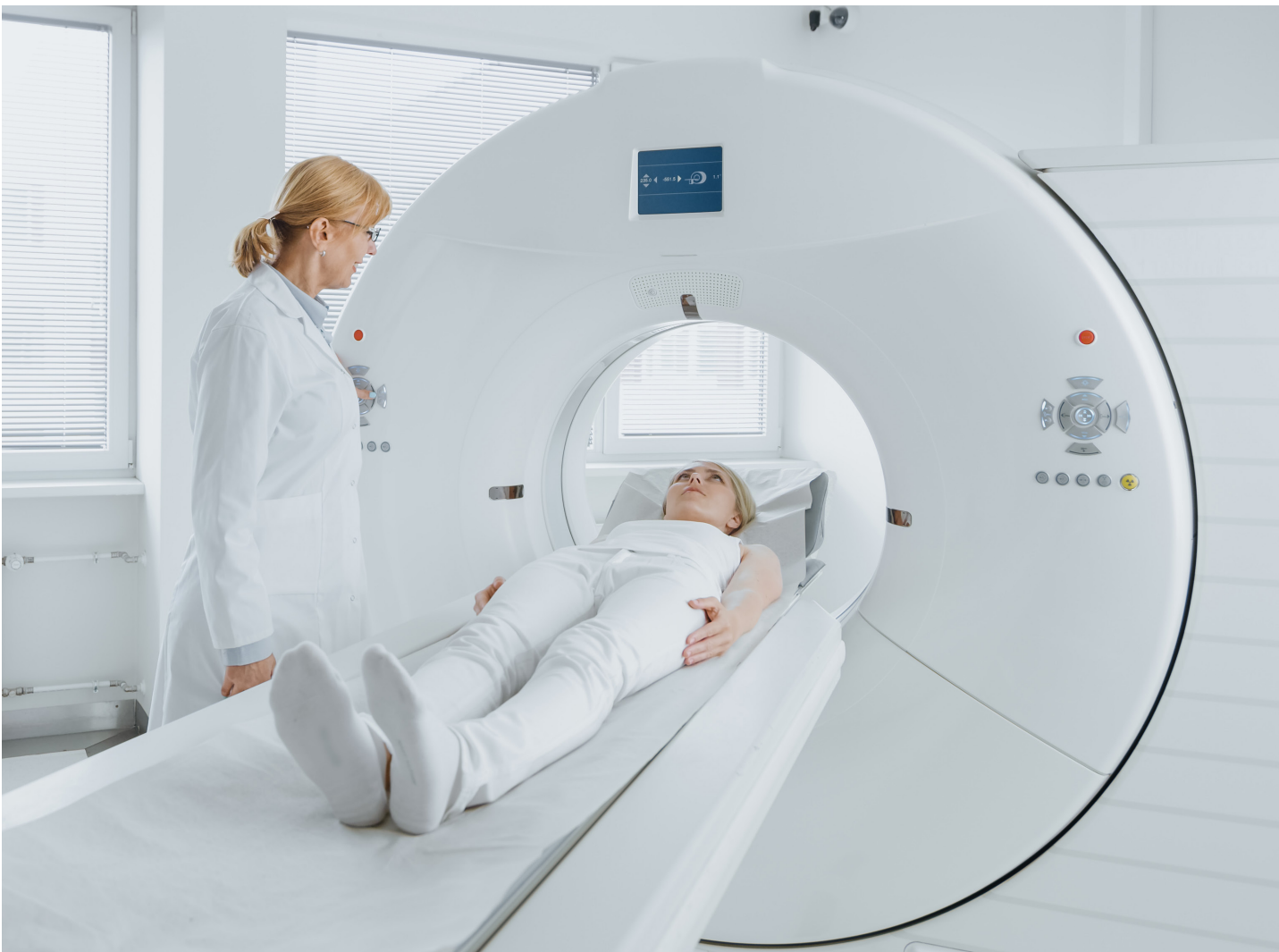8 How has the COVID-19 crisis affected your radiology practices for non-COVID-19 patients? Which patients/ radiological techniques might be most impacted if the crisis were to last several months?

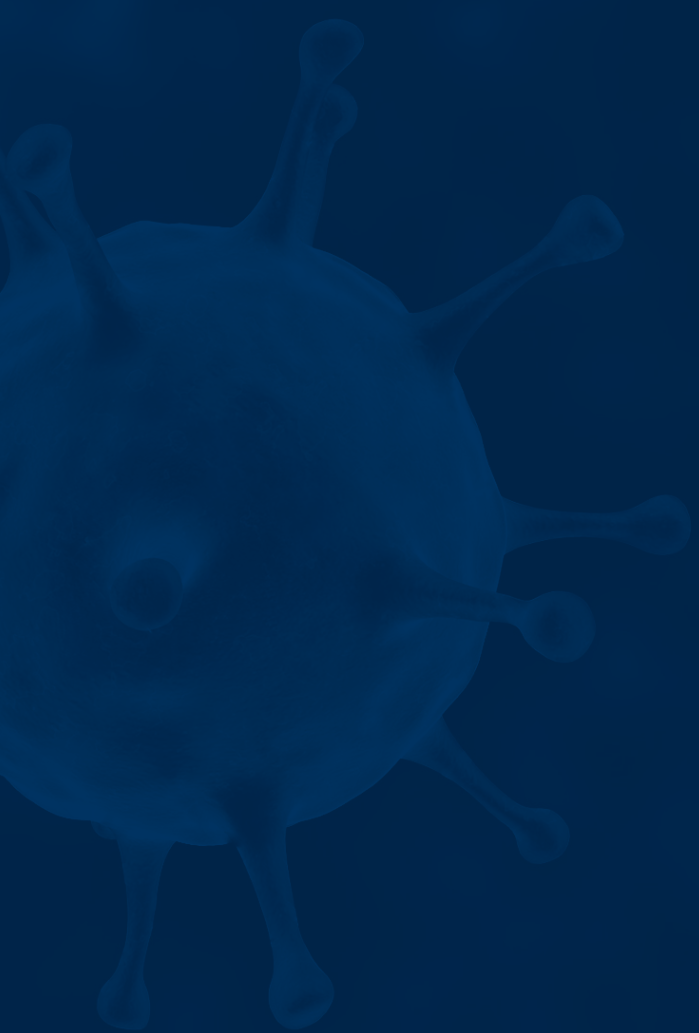
FA: Basically, the introduction of different circuits for COVID-19 and non-COVID-19 patients, as already mentioned. Probably focusing on chest X-rays and CT.

DI: The radiological techniques that would impact the radiology department most would be those for which "contact" between the patient and operator cannot be avoided. During the outbreak of the disease, for example, this meant that ultrasound and mammographic procedures suffered a lot. From a clinical point of view, the reduction in mammographic procedures had a great impact on patient outcome, as it was impossible to continue any screening or surveillance programs. This reduces the possibility of early detection of cancer and also treatment.

In addition, oncological patients with known cancer, who should have been undergoing standard radiological follow-up examinations, were treated cautiously to avoid the possibility of contracting the virus, given that they were already immunocompromised by their own disease. For this reason, we created a priority list of urgent patients in collaboration with our oncology physician and postponed the less urgent cases.

AK: The COVID-19 crisis has had a definite effect on non-COVID-19 patients, it has frightened them, and they tend to endure more of their symptoms, resulting in late diagnosis and even a drying up of therapeutic options. Elderly patients would be greatly impacted by a long-term crisis; in addition to being at risk for COVID-19, they tend to put off consulting doctors, resulting in late treatment. As for imaging techniques, ultrasound, MRI for non-disabling and no-risk symptoms (especially musculoskeletal MRI) and to a lesser degree comfort-related interventional radiology would all be impacted by the crisis.





Guerbet | 